

A PRELIMINARY STUDY ON THE METHOD OF TIME MARKING WITH LEAD SALT AND TETRACYCLINE ON THE TEETH OF FUR SEAL

TEIJI YAGI*, MASAHARU NISHIWAKI AND MASAYUKI NAKAJIMA**

Few studies have been so far reported on the technique of the age determination of fur seal. Scheffer (1950) described that the number of growth ridges appearing on the root of the canine tooth indicated the age of fur seal. Matsumoto (1958) developed the age-reading technique on the basis that the number of the transparent zones of the dentine corresponds to that of the growth rings on the surface of the teeth.

Kubota *et al.* (1961) stated that the transparent zone observed in the longitudinal ground section of the dentine terminates at the top of the growth ridge on the dental root. After histological studies, they have also found that the interglobular spaces, the granular layer of Tomes, and the transparent zone are formed in regular turn every year in the dentine.

The method of counting the number of annual rings of the contour or of the transparent bands of the dentine is rather easy and this is in practical use for the young animal. But the method is more difficult in the case of older animal, because the annual rings deposited become closer together with age. In addition, some thinner transparent zones of the dentine appear occasionally between two annually formed transparent dentines in many specimens especially of female. One of the practical difficulties and confusions in determining the age comes mainly from these zones in the case of the ground section of the dentine.

The present paper is a preliminary study to clarify the developmental process of the dentine by recording the time by the following two methods of intravital staining for hard tissues. The first is the modified method with lead acetate devised by Okada and Mimura (1938) and the second is with tetracycline adopted by Milch *et al.* (1957). Nishiwaki *et al.* (1953) reported that the method using lead acetate (dose of 5 mg of lead acetate per kg. of body weight by intramuscular injection) is applicable for the time-marking of the dolphin-tooth.

As to the method using tetracycline, many studies so far reported show that this antibiotic tends to combine with calcium when deposited. After administration of tetracycline to an animal an induced fluorescence can be detected in the tissues where tetracycline is distributed.

MATERIAL AND METHODS

In the present experiment a female fur seal of 25 kg. in body weight caught on

* Institute for Hard Tissues, Tokyo Medical and Dental University.

** Enoshima Aquarium.

June 16, 1959 in the water off Ozuchi, Iwate Prefecture, Japan, was used for this purpose.

The animal received the injections on August 27, 1959, after rearing about two-month period in the pond of the Enoshima Marineland (an aquarium). An injection containing lead complex salt was prepared by mixing lead acetate with sodium citrate in the rate of 1 : 3 and was administered intramuscularly into the nates. The dose was 5 mg of lead acetate per kg. of body weight. Tetracycline hydrochloride prepared commercially was administered by a single muscular injection in the dose of 4 mg per kg. of body weight, followed for seven days by the same dose contained in each of the twice daily diet. Therefore, the animal received the total amounts of 1500 mg of tetracycline administered orally or parenterally.

The animal survived for 162 days after the initial injection. The canine teeth which were removed from the dead animal were fixed in a 10% neutralized formalin solution. The teeth were decalcified in the 0.2 N hydrochloric acid saturated with hydrogen sulfide, and then cut into frozen sections. They were next immersed in a 0.1% solution of gold trichloride then in a 5% sodium thiosulfate solution to obtain a gilded lead line.

In order to observe the localization of tetracycline undecalcified ground sections of the teeth, approximately 50 μ thick, were put to microscopic examination for induced fluorescence under ultraviolet illumination. The microphotographs were taken with the aid of an orange filter.

RESULT AND DISCUSSION

The line made by the deposition of lead was found in the sections of the teeth prepared by the procedure given above. Fig. 1 shows the deposited line in the middle of the developing dentine. The fluorescent structure characteristic to the deposition of tetracycline is shown in Fig. 2 in which the structure is apparently demonstrated as bright yellow line or band under the ultraviolet light.

As shown in these figures the lines, both of lead acetate and tetracycline, are located in the position of the growth layer of the dentine which is formed practically at the same time as the development of the dentine. This portion of the dentine confined between the marked line and the predentine corresponds to the increase during a five-month period from August 27 to February 2. The longitudinal ground section of the tooth shows that the age of the fur seal is identified as approximately four years by counting the contour growth ridges or transparent zones of the dentine (PLATE II-A).

In the sections of the dentine some peculiar lines presumably caused by metabolic disturbances in the development of the dentine were observed. The first line, the outermost of the dentine, was recognized as the neonatal line. The last one, coincided in position with the marking line, seemed to be caused by the administration of tetracycline (PLATE III). It is already known that the administration of tetracycline depresses the calcification either in skeleton or in tooth, while lead acetate in the appropriate doses shows no effect in development of the calcified

tissues. In the tetracycline method a ground section must be prepared, since the drug is removed by the delayed treatment for decalcification.

In the present experiment tetracycline was given to the animal by separate administration for seven successive days in the dose of 60 mg per kg. of body weight. From the result obtained, a single dose of tetracycline possibly less than 60 mg per kg. may produce a detectable fluorescence in the area where calcification takes place. It was noted that an adequate amount of tetracycline available for the ultraviolet examination persisted within the dentine over 24 months after the death of the animal.

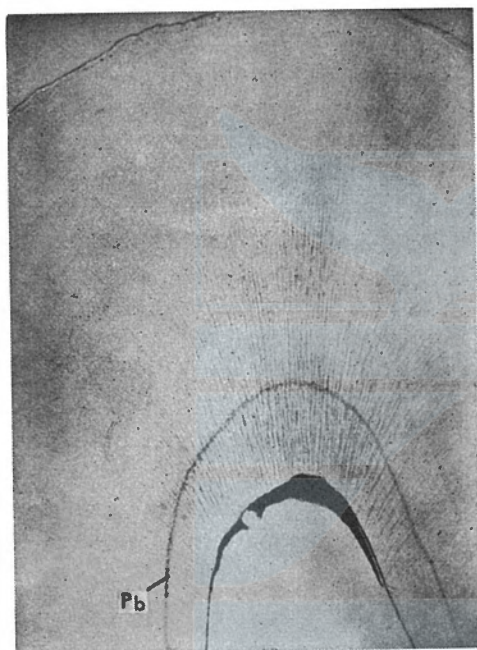


Fig. 1. Transverse section of right mandible canine, 162 days after the injection of lead complex salt. Pb: Line of deposited lead.




Fig. 2. Transverse section of left mandible canine, around 158 days after the administration of tetracycline, under ultraviolet light. TC: Fluorescent line of deposited tetracycline. A: Line of autofluorescence.

Further study is in progress for marking the time with lead salt and tetracycline on the fur seal dentine so as to clarify the mechanisms of annual ring formation and to establish the method of the age determination.

The authors wish to express their hearty appreciation to Prof. Masahiro Okada, president of Tokyo Medical and Dental University, for his admirable guidance, and to Prof. Akira Asoda for his kind suggestion in this study. Grateful acknowledgement is made to Dr. Fukuzo Nagasaki, Tokai Regional Fisheries Research Laboratory, for collecting the specimens and for much discussion. They also wish to acknowledge the plentiful labour in rearing the fur seal to the members of the Enoshima Marineland. Their thanks are due also to the helpful suggestion

of Mr. Izumi Morisaki in the course of studying fluorescence.

SUMMARY

Intravital staining after the modified lead acetate method and tetracycline for marking the time on the dentine of the fur seal was carried out, in order to establish a reliable method for the age determination of this animal. A female fur seal received the drugs and survived for 162-day period.

1. Lead acetate was given intramuscularly in the dose of 5 mg per kg. of body weight. The injection containing lead complex salt by adding sodium citrate to lead acetate, produced deposited line of lead in the area of the dentine in which matrix calcification took place. The lead line was demonstrable histochemically in the decalcified sections.

2. Tetracycline was given in the dose of 60 mg per kg. of body weight orally and parenterally. The administration of this was divided into seven successive days and given practically at the same time as the lead injection. The line of tetracycline-induced fluorescence was evident in the ground section of the dentine under the ultraviolet illumination.

3. Two lines produced by deposition of lead and tetracycline were localized in the same position of the dentine. The width of dentine enclosed by the marked band revealed the increase of the dentine during a five-month period from September to January.

4. It was estimated that the fur seal was about four years old both from those results and from the annual rings on the root and the dentine.

5. The methods described here may be adopted as a technique for the age determination especially in the older animal in which the pattern of the annual rings is not well defined.

REFERENCES

- BEVELANDER, G., ROLLE, G. K. and COHLAN, S. Q. (1961). The effect of the administration of tetracycline on the development of teeth. *Jour. Dent. Res.*, 40: 1020-1024.
- HARRIS, W. H. (1960). A microscopic method of determining rates of bone growth. *Nature*, 188: 1038-1039.
- KUBOTA, K., NAGASAKI, F., MATSUMOTO, K. and TSUBOI, M. (1961). Histological studies on the growth layers in the maxillary canines of fur seals as an indicator of age. Part 1. The teeth at the age of one to nine year. *Bull. Tokyo Med. Dent. Univ.*, 8: 261-285.
- MATSUMOTO, K. (1958). Unpublished, manuscript.
- MILCH, R. A., RALL, D. P. and TOBIE, J. E. (1957). Bone localization of the tetracyclines. *Jour. Natl. Cancer Inst.*, 19: 87-91.
- MILCH, R. A., TOBIE, J. E. and ROBINSON, R. A. (1961). A Microscopic study of tetracycline localization in skeletal Neoplasma. *Jour. Histochem. Cytochem.*, 9: 261-270.
- NAGASAKI, F. (1961). Population study on the fur-seal herd. *Special Publication, Tokai Regional Fisheries Research Laboratory*, 7: 1-60.
- NISHIWAKI, M. and YAGI, T. (1953). On the age and the growth of teeth in a dolphin, (*Prodelphinus caeruleo-albus*). (I). *Sci. Rep. Whales Res. Inst.*, 8: 133-145.

- NISHIWAKI, M. and YAGI, T. (1954). On the age-determination method of the toothed whale by the study of the tooth. *Proc. Jap. Acad.*, 30 399-404.
- NISHIWAKI, M., HIBIYA, T. and OHSUMI, S. (1958). Age study of sperm whale, based on reading of tooth laminations. *Sci. Rep. Whales Res. Inst.*, 13: 135-154.
- OKADA, M. and MIMURA, T. (1938). Zur Physiologie und Pharmakologie der Hartgewebe. I. Mitteilung: Eine Vitalfarbungsmethode mit Bleisalzen und ihre Anwendung bei den Untersuchungen über die rhythmische Streifenbildung der harten Zahngewebe. *Jap. Jour. Med. Sci., IV Pharmacology*, 11: 166-170.
- SCHEFFER, V. B. (1950). Growth layers on the teeth of pinnipedia as an indication of age. *Science*, 112: 309-311.
- SCHOUR, I. and KRONFELD, R. (1939). Neonatal dental hypoplasia. *Jour. Amer. Dent. Assn.*, 26: 18-32.

EXPLANATION OF PLATES

PLATE I

Ventral view of the skull (A), dorsal view of the mandible (B), the left mandible canine (C) and the left maxillary canine (D) of the fur seal, 25 kg. weight female, used in this observation.

PLATE II

Longitudinal ground section of left maxillary canine of the fur seal (A) compared with a specimen of 4-year-old female (B).

N: Neonatal line. T-1, 2, 3: Transparent zone of the dentine.

PLATE III

Longitudinal ground section of left maxillary canine of the fur seal, around 158 days after the administration of tetracycline, under ultraviolet light (A) and under tungsten light (B).

TC: Fluorescent line of deposited tetracycline.

A: Line of auto-fluorescence.

