

AN OBSERVATION ON THE PAPILLARY PROJECTIONS AT THE LINGUAL MARGIN IN THE STRIPED DOLPHIN

FUSAO YAMASAKI

Department of Biology, Sapporo Medical College, Sapporo

HAJIME SATOMI

Department of Anatomy, Sapporo Medical College, Sapporo

AND

TOSHIRO KAMIYA

Department of Anatomy, Faculty of Medicine, University of Tokyo, Tokyo

ABSTRACT

Papillary projections were observed along the anterolateral margins of the tongue in fetal and young stages of the striped dolphin, *Stenella coeruleoalba*. The projections appear in the fetal stage and attain maximum development in the early postnatal period. They disappear almost completely by weaning, although small vestigial eminences remain at the corresponding region in the adult. The projections may have a close relation to suck milk.

There are few descriptions of the anatomy of the tongue in Cetacea, and many uncertainties remain concerning lingual structure and function in many species of this order of mammals. One of the most remarkable features of the tongue in Cetacea is the completely absence of lingual papillae.

We have found papilla-like projections at the anterolateral margin of the tongue in fetal and young individuals of some species of dolphins. Growth and involution of these projections were demonstrated in the striped dolphin, *Stenella coeruleoalba*. The fact that the projections appear temporarily, and do not persist throughout life, has not been reported previously.

As shown in Fig. 1, small projections, approximately 0.5 mm in length and about twenty in number on each side, are present at the lateral margins of the anterior one-third of the body of the tongue in a 27 cm fetus. The projections are distinct (1 to 2 mm long) occupying the entire anterior margin of the tongue in an 80 cm fetus. In a 98 cm fetus, they have grown longer (2 to 5 mm) and wider than those in the 80 cm fetus (Fig. 2) and some of them are subdivided at their tips (arrows in Fig. 2). In a young *Stenella* (body length 150 cm), projections have become somewhat thinner and broken, and some of them have disappeared in the posterior part (Fig. 3). In an adult animal, several distinct

eminences are present near the apex of the tongue (Fig. 4). In another larger adult one, the eminences have reduced in size and the lateral margins are slightly uneven in appearance. The entire dorsum of each tongue we observed was quite smooth and no lingual papillae of any type were present.

Since the body length of *Stenella coeruleoalba* is about 100 cm at the time of birth (Kasuya, 1972), the appearance of the tongue in the newborn animal is probably similar to that in the 98 cm fetus we observed. Thus, it is certain that the papillary projections in the *Stenella* appear during intrauterine life and gradually develop towards parturition. The projections may be most numerous and well developed in the early postnatal period and they may begin to degenerate and disappear at about the 150 cm stage, which roughly corresponds to weaning in *Stenella coeruleoalba* (Kasuya, 1972). How the number of the projections increase and how the projections disappear are interesting points. It can be assumed that the former increase due to subdivision of the projections that are present in the 98 cm fetus as shown with arrows in Fig. 2, and the latter vanish through repeated narrowings in several parts of each projection (arrows in Fig. 3) and finally shed off from the tongue proper.

In the adult Franciscana dolphin, *Pontoporia blainvillei*, no papillae were present on the dorsum of the tongue but small eminences were observed at its lateral margins. Distinct papillary projections (2 to 3 mm long) were found at the anterior free margin of the tongue in a young, 98.5 cm, *Pontoporia* (Yamasaki, *et al.*, 1976), and the same region was dotted with warts and fringes in a young animal (Burmeister, 1869). The small eminences at the anterolateral margins of the tongue of the adult *Stenella* and also of the adult *Pontoporia* appear to be the remnants of the papillary projections seen in the young animals. We also observed well developed projections (2 to 4 mm long) at the anterior margin of the tongue in a newborn finless porpoise, *Neophocaena phocaenoides* (71.5 cm). And foliate projections (3 to 6 mm), which decrease in their number with age, were observed in young bottlenose dolphin, *Tursiopus truncatus*, and Risso's dolphins, *Grampus griseus* (Nakajima, *et al.*, 1963). Thus, the papillary projections will be found in the fetuses and the young of some other dolphins or toothed whales. Although Anderson (1879) and Sonntag (1922) described filiform and fungiform papillae on the tongue of Ganges dolphin, *Platanista gangetica*, the dorsum of the tongues of the adults was completely smooth and no type of lingual papillae could be observed (Arvy and Pilleri, 1970, Yamasaki, *et al.*, 1976). As they only observed the tongue in the young stage without observation in the adult, projections were probably described as the lingual papillae mentioned above.

The projection is composed of a core of the lamina propria mucosa and a thick stratified squamous epithelium without taste buds. Both are continuous with those of the tongue proper. This structure, as a whole, is similar to that of filiform or fungiform papillae. However, the projections differ markedly from the lingual papillae of the general mammalian tongue in that they are temporary, localized at the anterolateral margin in a radial manner and large

in size. Sonntag (1922) stated that the apex of the tongue in toothed whales may or may not have processes and warty growths, however, we suppose that he observed the tongues in variable stages of involution of the papillary projections. Since the projections only appear in a specific period during life, more care is necessary as to the estimation of the age when observing the appearance of the cetacean tongue.

The function of the lingual papillary projections described above is not known. Because they are well developed during the suckling period they may have an important mechanical functions during suckling in these aquatic mammals.

As there as yet seem to be several unclear and interesting problems concerning the papillary projections in dolphins, further observations will be done on the relationship between the existence of the projections and the suckling period as well as on food habits and on the process of their development and degeneration, macro- and microscopically. In addition, comparative functional anatomical studies with other cetaceans will be necessary to clarify this problem.

ACKNOWLEDGMENTS

Greatest thanks are due to Dr. M.M. Bryden, School of Anatomy, University of Queensland, Australia, who gave us valuable suggestions and kindly checked the draft. Dr. T. Mitsui, Department of Anatomy, Keio University, Dr. T. Ogawa, Department of Medical History, Juntendo University, Dr. K. Takahashi, Department of Anatomy, Sapporo Medical College, Dr. H. Ohmura, Whales Research Institute, Dr. T. Kasuya, Ocean Research Institute, University of Tokyo, and Dr. R.L. Brownell Jr., Department of Vertebrate Zoology, National Museum of Natural History, Washington, D.C. are also acknowledged for their advice for our study.

REFERENCES

- ANDERSON, J., 1879. Anatomical and zoological researches: comprising on account of the zoological results of the two expeditions to Western Yunnan 1868 and 1875; and a monograph of the two cetacean genera, *Platanista* and *Orcella*. Vol. 1, pp. 433-435, Quaritch, London.
- ARVY, L. and G. PILLERI, 1970. The tongue of *Platanista gangetica* and remarks on the cetacean tongue. In: *Investigation on cetacea.*, Vol. II, ed. by G. Pilleri, 75-77, Berne.
- BURMEISTER, H., 1869. In: Descripción de cuatro especies de delfinides de la costa Argentina en el Océano Atlántico. *Anal. Mus. Público Buenos Aires.*, 1: 348-445.
- KASUYA, T., 1972. Growth and reproduction of *Stenella caeruleoalba* based on the age determination by means of dentinal growth. *Sci. Rep. Whales Res. Inst.*, 24: 57-79.
- NAKAJIMA, M., K. TAKAHASHI, M. OGURA, and K. SAWAMURA, 1963. On the growth of infants of the small size toothed whales. *J. Jap. Assoc. Zool. Gard. Aqua. Tokyo*, 5: 16-22. (in Japanese with English summary).
- SONNTAG, C. F., 1922. The comparative anatomy of the tongue of the Mammalia. VII, Cetacea, Sirenia and Ungulata. *Proc. Zool. Soc.*, 639-646.
- YAMASAKI, F., H. SATOMI, and T. KAMIYA, 1976. The tongue of Franciscana (La Plata) dolphin, *Pontoporia blainvillei*. *Okajimas Fol. anat. jap.*, 53: 77-92.

EXPLANATION OF PLATE I

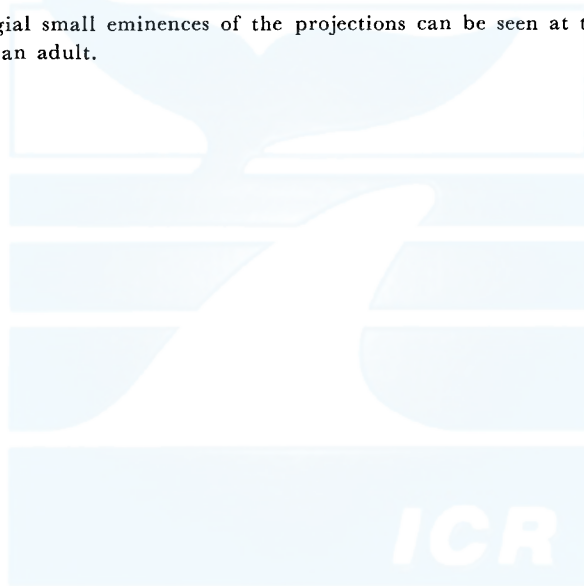
Four stages of the growth and degeneration of the lingual papillary projections of the striped dolphin, *Stenella coeruleoalba*.

Fig. 1. Small projections have already appeared at the lateral margin of the anterior part of the tongue in a 27 cm fetus.

Fig. 2. Projections in a 98 cm fetus are distinct and occupy the entire anterior margin of the tongue in a radial manner. Some of the projections are subdivided at their tips (arrows). The dorsum of the tongue is concave along the long axis.

Fig. 3. In young *Stenella* (150 cm), projections have become thinner and some at the posterior part have been broken and have disappeared. Note the narrowing seen in some projections (arrows). The transverse and longitudinal incisions were made to improve fixation.

Fig. 4. Vestigial small eminences of the projections can be seen at the margin near the apex in an adult.



一般財団法人 日本鯨類研究所
THE INSTITUTE OF CETACEAN RESEARCH

